

THE JOURNAL OF BONE & JOINT SURGERY

# JB&JS

*This is an enhanced PDF from The Journal of Bone and Joint Surgery*

*The PDF of the article you requested follows this cover page.*

---

## **Eccentric Loading Compared with Shock Wave Treatment for Chronic Insertional Achilles Tendinopathy. A Randomized, Controlled Trial**

Jan D. Rompe, John Furia and Nicola Maffulli  
*J Bone Joint Surg Am.* 2008;90:52-61. doi:10.2106/JBJS.F.01494

---

**This information is current as of January 17, 2008**

### **Supplementary material**

Commentary and Perspective, data tables, additional images, video clips and/or translated abstracts are available for this article. This information can be accessed at <http://www.ejbjs.org/cgi/content/full/90/1/52/DC1>

### **Reprints and Permissions**

Click here to [order reprints or request permission](#) to use material from this article, or locate the article citation on [jbjs.org](http://jbjs.org) and click on the [Reprints and Permissions] link.

### **Publisher Information**

The Journal of Bone and Joint Surgery  
20 Pickering Street, Needham, MA 02492-3157  
[www.jbjs.org](http://www.jbjs.org)

# Eccentric Loading Compared with Shock Wave Treatment for Chronic Insertional Achilles Tendinopathy

## A Randomized, Controlled Trial

By Jan D. Rompe, MD, John Furia, MD, and Nicola Maffulli, MD, PhD, FRCS(Orth)

*Investigation performed at the OrthoTrauma Clinic, Gruenstadt, Germany*

**Background:** Nonoperative management of chronic tendinopathy of the Achilles tendon insertion has been poorly studied. With the recently demonstrated effectiveness of eccentric loading and of repetitive low-energy shock wave therapy in patients with midsubstance Achilles tendinopathy, the aim of the present randomized, controlled trial was to verify the effectiveness of both procedures exclusively in patients with insertional Achilles tendinopathy.

**Methods:** Fifty patients with chronic (six months or more) recalcitrant insertional Achilles tendinopathy were enrolled in a randomized, controlled study. All patients had received treatment, including local injections of an anesthetic and/or corticosteroids, a prescription of nonsteroidal anti-inflammatory drugs, and physiotherapy, without success for at least three months. A computerized random-number generator was used to draw up an allocation schedule. Twenty-five patients were allocated to receive eccentric loading (Group 1), and twenty-five patients were allocated to treatment with repetitive low-energy shock wave therapy (Group 2). Analysis was on an intention-to-treat basis. Primary follow-up was at four months, and afterward patients were allowed to cross over. The last follow-up evaluation was at one year after completion of the initial treatment. The patients were assessed for pain, function, and activity with use of a validated questionnaire (the Victorian Institute of Sport Assessment-Achilles [VISA-A] questionnaire).

**Results:** At four months from baseline, the mean VISA-A score had increased in both groups, from 53 to 63 points in Group 1 and from 53 to 80 points in Group 2. The mean pain rating decreased from 7 to 5 points in Group 1 and from 7 to 3 points in Group 2. Seven patients (28%) in Group 1 and sixteen patients (64%) in Group 2 reported that they were completely recovered or much improved. For all outcome measures, the group that received shock wave therapy showed significantly more favorable results than the group treated with eccentric loading ( $p = 0.002$  through  $p = 0.04$ ). At four months, eighteen of the twenty-five patients from Group 1 had opted to cross over, as did eight of the twenty-five patients from Group 2. The favorable results after shock wave therapy at four months were stable at the one-year follow-up evaluation.

**Conclusions:** Eccentric loading as applied in the present study showed inferior results to low-energy shock wave therapy as applied in patients with chronic recalcitrant tendinopathy of the insertion of the Achilles tendon at four months of follow-up. Further research is warranted to better define the indications for this treatment modality.

**Level of Evidence:** Therapeutic Level I. See Instructions to Authors for a complete description of levels of evidence.

Achilles tendon injuries occur frequently in runners and in athletes who play sports that involve jumping, and they are also common in the general population. The precise etiology and natural history of these injuries remains unknown<sup>1,2</sup>.

Khan et al.<sup>3</sup> and Maffulli et al.<sup>4-6</sup> popularized the term Achilles tendinopathy to describe the triad of tendon pain, swelling, and impaired performance. From a functional perspective, it is helpful to classify Achilles tendinopathy as insertional<sup>6</sup>—symptoms that occur at the bone-tendon

**Disclosure:** The authors did not receive any outside funding or grants in support of their research for or preparation of this work. Neither they nor a member of their immediate families received payments or other benefits or a commitment or agreement to provide such benefits from a commercial entity. No commercial entity paid or directed, or agreed to pay or direct, any benefits to any research fund, foundation, division, center, clinical practice, or other charitable or nonprofit organization with which the authors, or a member of their immediate families, are affiliated or associated.

junction—or as noninsertional<sup>5</sup>—those that occur more proximally.

Although Achilles tendinopathy has been studied extensively, there is a clear lack of properly conducted scientific research to clarify its optimal management<sup>4,6-8</sup>. In a recent Cochrane review<sup>9</sup>, only nine clinical trials, consisting of 697 patients, were of sufficient quality to be considered. Overall, there was insufficient evidence from the randomized, controlled trials to determine which method is the most appropriate to manage Achilles tendinopathy, and not a single trial concentrated exclusively on the treatment of insertional Achilles tendinopathy.

Several studies have demonstrated that eccentric training can be an effective treatment for insertional and noninsertional tendinopathies<sup>10-14</sup>, although Woodley et al.<sup>15</sup> recently stressed the dearth of high-quality research in support of the clinical effectiveness of eccentric exercises over other treatments. In an uncontrolled observational study, a twelve-week eccentric calf-muscle strength-training program led to a satisfactory outcome in 89% of 101 patients with chronic painful Achilles tendinosis at the midportion<sup>13</sup>.

Information regarding the application of shock wave treatment for Achilles tendinopathy is sparse<sup>16,17</sup>. Costa et al.<sup>18</sup> found no difference in pain relief between repetitive low-energy shock wave treatment and a placebo group<sup>19</sup>. Rompe et al.<sup>20</sup>, in a triple-arm randomized, controlled trial comparing eccentric loading, repetitive low-energy shock wave therapy, and a wait-and-see policy in the treatment of midsubstance Achilles tendinopathy, found that eccentric loading and shock wave treatment yielded comparable success rates (60% and 52%, respectively), which were substantially better than the wait-and-see policy (24%). Again, we know of no single randomized clinical trial concentrating exclusively on the treatment of insertional Achilles tendinopathy.

We compared the efficacy of two protocols, eccentric calf-strengthening and repetitive low-energy shock wave therapy, for the treatment of chronic insertional Achilles tendinopathy.

## Materials and Methods

We performed a randomized trial in a primary-care setting, enrolling patients from the general population who had consulted one of three participating orthopaedic physicians for Achilles tendon complaints. The patients were then referred to the clinic of one of us (J.D.R.) (Table I). In all patients, the diagnosis of tendinopathy at the insertion of the Achilles tendon (synonymous with insertional Achilles tendinopathy) was confirmed clinically. For this purpose, insertional Achilles tendinopathy was defined as localized pain over the distal part of the Achilles tendon at its insertion onto the calcaneus, with local tenderness and a reduced level of activity<sup>6</sup>. The Williams arc sign test<sup>21</sup> and the Royal London Hospital test<sup>4</sup> were applied to rule out more extensive tendinopathy or paratendinopathy involving the body of the Achilles tendon. In all patients enrolled in the study, an ultrasound study also excluded thickening of the tendon and/or an irregular tendon structure with hypochoic areas and/or an irregular fiber ori-

entation in the midportion of the tendon<sup>22</sup>. Patients presenting with superficial or retrocalcaneal fluid on the ultrasound examination as a sign of bursitis were excluded. All patients had plain radiographs of the calcaneus to identify tendon calcification. Patients showing a Haglund deformity, an osseous prominence on the posterosuperior and lateral aspect of the calcaneus with a Fowler-Philip angle of  $>75^\circ$  on plain radiographs<sup>23</sup>, were excluded.

We included patients who had an established diagnosis of chronic insertional Achilles tendinopathy for at least six months combined with failure of nonoperative management, including at least one injection of a local anesthetic and/or a corticosteroid, a prescription for an anti-inflammatory medication, and physiotherapy and/or use of orthotics or a heel lift. Patients were between the ages of eighteen and seventy years, and they had to be able to complete questionnaires and to give informed consent.

We excluded from the study those patients who had received peritendinous injections (local anesthetic and/or corticosteroids) within the previous four weeks, patients in whom symptoms had been present for less than six months, and patients with other conditions that could contribute substantially to posterior ankle pain, such as classic midsubstance Achilles tendinopathy, ankle arthritis, radiculopathy, or systemic neurological conditions. Patients were also excluded if they had congenital or acquired deformities of the knee and ankle, prior surgery of the ankle or the Achilles tendon, a prior Achilles tendon rupture, or a dislocation or fracture in the area in the preceding twelve months.

## Study Protocol

A nurse who was not directly involved in the management of the patients checked all selection criteria and enrolled fifty patients. Informed consent was obtained. The local medical ethics committee had approved the protocol.

A computerized random-number generator was used to formulate an allocation schedule. Subjects were randomized to either treatment, with use of the method of randomly permuted blocks. The randomization scheme was generated with use of the web site [www.randomization.com](http://www.randomization.com). Fifty patients were randomized into five blocks. The assignment of patients to eccentric loading or to shock wave therapy took place after final selection and baseline assessment by the senior author (J.D.R.). A medical assistant allocated interventions by means of opaque sealed envelopes that were marked according to the allocation schedule (Fig. 1). The medical assistant was unaware of the size of the blocks.

Patients were asked to avoid pain-provoking activities throughout the twelve-week treatment period. Walking and bicycling were allowed if they could be performed with only mild discomfort. Light jogging on flat ground and at a slow pace was allowed after four to six weeks, but only if it could be undertaken without pain. Thereafter, activities could be gradually increased if severe tendon pain did not occur.

The option to cross over to the other treatment group or to choose any other therapy was provided to patients who

TABLE I Baseline Characteristics of Patients

Characteristic	Group 1 (Eccentric Loading) (N = 25)	Group 2 (Shock Wave Therapy) (N = 25)
Age* (y)	39.2 (10.7)	40.4 (11.3)
Female patients†	14 (56)	16 (64)
Duration of symptoms* (mo)	24.8 (8.2)	26.3 (10.7)
Nonathletic patients†	11 (44)	10 (40)
Athletic patients†	14 (56)	15 (60)
Affected feet (no. [%] of feet)	30 (100)	31 (100)
Left feet	13 (43)	15 (48)
Right feet	17 (57)	16 (52)
Previous treatment‡		
Nonsteroidal anti-inflammatory drugs	25 (100)	25 (100)
Physical therapy	25 (100)	25 (100)
Orthotics	25 (100)	25 (100)
Conventional stretching exercises	25 (100)	25 (100)
Injections	25 (100)	25 (100)
≥2 cortisone injections	14 (56)	12 (48)
Shock wave therapy	0 (0)	0 (0)
Surgery	0 (0)	0 (0)
VISA-A score*‡	52.7 (8.4)	53.2 (5.8)
General assessment rated on 6-point Likert scale*	5.4 (0.6)	4.9 (0.9)
Load-induced pain assessed on a numeric rating scale from 0 to 10*	6.8 (1.0)	7.0 (0.8)
Pain threshold* (kg)	1.4 (0.7)	1.6 (0.8)
Tenderness at 3 kg assessed on a numeric rating scale from 0 to 10*	6.2 (3.7)	6.5 (3.4)

\*The values are given as the mean, with the standard deviation in parentheses. †The values are given as the number of patients, with the percentage in parentheses. ‡The VISA-A (Victorian Institute of Sport Assessment-Achilles questionnaire) ranged from 1 to 100.

did not feel that they had completely recovered or had much improvement at four months after the start of the trial.

### Methods of Treatment

#### Eccentric Training

Patients were instructed on how to perform the eccentric training<sup>13,14,24,25</sup>. The senior author demonstrated how to perform the eccentric exercises to each patient on an individual basis. Patients were given practice instruction and a written manual on how to progress. Proper form and technique were assessed by a medical assistant after six weeks. In the beginning, the loading consisted of the body weight. The patient stood on a step with all of his or her body weight on the injured leg. From an upright body position and standing with all body weight on the forefoot, with the ankle joint in plantar flexion, the calf-muscle was loaded by having the patient lower the affected limb by dorsiflexing the ankle until the heel was well below the level of the step with the ankle in maximum dorsiflexion. The exercises were performed with the knee straight to load the gastrocnemius eccentrically and with the knee flexed to load the soleus eccentrically. Patients only loaded the calf-muscle eccentrically; no concentric loading was performed, as

the patients were instructed to use the uninjured leg and/or their arms to get back to the start position. Patients aimed to complete three sets of fifteen repetitions with one minute of rest between the sets twice a day, seven days per week, for twelve weeks. Patients started with one set of ten repetitions on the first day of exercises and gradually progressed to three sets of fifteen repetitions by the seventh day, aiming to complete three sets of fifteen repetitions twice a day by the second week of treatment. Patients were advised to continue the exercises through mild or moderate pain, stopping only if the pain became unbearable. When these exercises could be completed with no pain or discomfort, the patients progressed to carry a backpack containing 5 kg of books. They were invited to continue to add weight in multiples of 5 kg if they did not have pain in the Achilles tendon by the end of the third set of the eccentric exercises. The patients were asked to refrain from other forms of physical therapy and not to use insoles<sup>24</sup>. If necessary, paracetamol (2000 to 4000 mg daily) or naproxen (1000 mg daily) was prescribed. Patients were instructed to do the exercises on a daily basis, and they were asked if they had done so at the follow-up visits. However, rigid control of compliance was not possible.

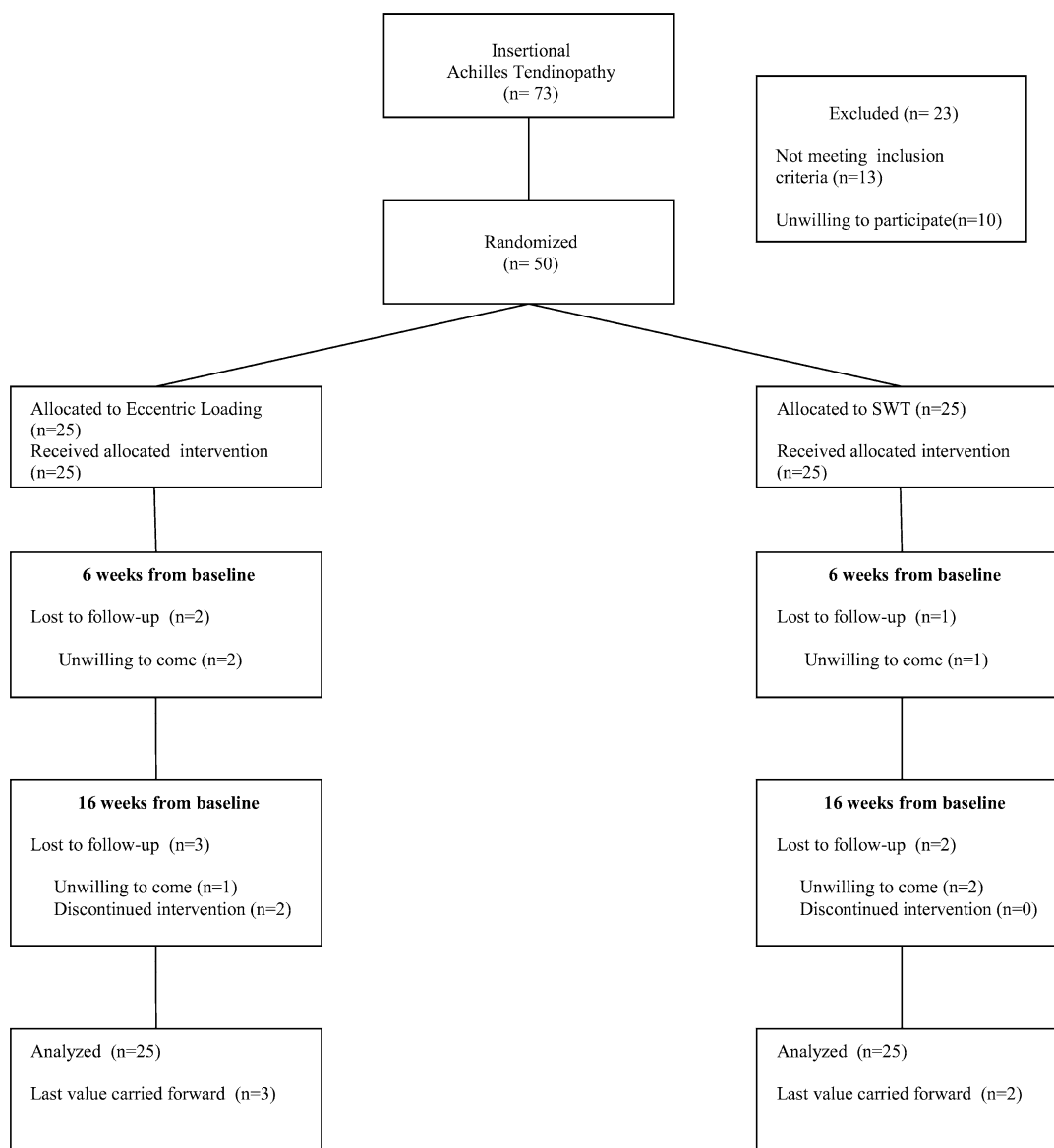


Fig. 1

Flow chart of the trial until the primary follow-up at four months from baseline. SWT = shock wave treatment.

### Shock Wave Therapy

Shock wave therapy was administered to the patients by the senior author. A radial shock wave device (EMS Swiss Dolor-Clast, Munich, Germany) was used. A projectile in a handpiece is accelerated by a pressurized air source and strikes a 15-mm-diameter metal applicator. The energy generated is transmitted to the skin as a shock wave through a standard, commercially available ultrasound gel. The wave then disperses radially from the application site into the tissue to be treated. The energy generated depends considerably on the working pressure to which the device has been set. Following our previous recommendation<sup>20</sup>, shock wave therapy was performed three times spaced one week apart. At each of the three sessions, 2000 pulses were applied with a pressure of 2.5 bars (equal to an energy flux density of 0.12 mJ/mm<sup>2</sup>). The treatment fre-

quency was eight pulses per second. With use of the principle of clinical focusing, the area of maximal tenderness was treated in a circumferential pattern, starting at the point of maximum pain. No local anesthetic was applied.

Details of each treatment session and of any adverse effects were reported on standardized forms and given to the medical assistant. All concomitant interventions during the four-month follow-up period were discouraged. If necessary, paracetamol (2000 to 4000 mg daily) or naproxen (1000 mg daily) was prescribed. Patients were encouraged to await further spontaneous improvement.

### Outcome Assessment

Following the investigations on eccentric loading by Alfredson<sup>12</sup> and Fahlstrom et al.<sup>13</sup>, the main follow-up point was chosen

TABLE II Outcome Assessment at the Four-Month Follow-up

Outcome Measure	Group 1 (Eccentric Loading)	Group 2 (Shock Wave Therapy)	Mean Difference Between Groups (Range)	Significance (P Value)
VISA-A score*†	63.4 ± 12.0 (28-100)	79.4 ± 10.4 (34-100)	16.2 (5.3 to 27.2)	0.005
General assessment rated on 6-point Likert scale*	3.7 ± 1.5 (1-6)	2.8 ± 1.6 (1-6)	-0.9 (-1.8 to 0.03)	0.043
Load-induced pain assessed on a numeric rating scale from 0 to 10*	5.0 ± 2.3 (1-8)	3.0 ± 2.3 (0-8)	-2.0 (-3.3 to 0.7)	0.004
Pain threshold* (kg)	2.2 ± 1.6 (1.6-4.5)	3.5 ± 1.1 (1.5-5.2)	1.3 (0.5 to 2.1)	0.002
Tenderness at 3 kg assessed on a numeric rating scale from 0 to 10*	4.4 ± 3.2 (1-8)	2.4 ± 4.2 (1-7)	-2.0 (-3.7 to 0.3)	0.021

\*The values are given as the mean and the standard deviation, with the range in parentheses. †The VISA-A (Victorian Institute of Sport Assessment-Achilles questionnaire) ranged from 1 to 100.

at four months from baseline. This meant that observer-blinded outcome assessments were performed before randomization and at sixteen weeks after baseline assessment (four weeks after the end of the twelve-week eccentric loading program and twelve weeks after the last shock wave therapy session) (Table II). A third evaluation took place at fifteen months from baseline (twelve months after completion of the eccentric training program and fourteen months after the final shock wave therapy session).

#### VISA-A Score

At each visit, every patient completed the VISA-A (Victorian Institute of Sport Assessment-Achilles) questionnaire, which is validated for Achilles tendon problems<sup>26</sup>. It contains eight questions that cover the three domains of pain (questions one, two, and three), function (questions four, five, and six), and activity (questions seven and eight). Questions one through seven are scored on a basis of 10 points, and question eight has a maximum of 30 points. Scores are summed to give a total. An asymptomatic person would score 100.

#### General Assessment

General outcome was scored by the patient on a 6-point Likert scale, with 1 indicating complete recovery<sup>27</sup>. For the computation of success rates, patients who rated the result as 1 or 2 (i.e., completely recovered or much improved) were counted as having a successful outcome.

#### Pain Assessment

Patients also scored the severity of their main complaint, pain during the day, on an 11-point numeric rating scale (with 0 indicating no pain and 10, very severe pain).

An algometer (Pain Test-Model FPK; Wagner Instruments, Greenwich, Connecticut) was used as a semiobjective measuring device that allows assessment of the pressure pain threshold and tenderness. The pain threshold was defined as the minimum pressure applied through the 1-cm<sup>2</sup> tip, which induced pain in the most tender area of the Achilles

tendon insertion. Tenderness was defined as the pain rating on a numeric rating scale induced when a pressure of 3 kg was applied to the most tender area of the Achilles tendon insertion.

Finally, the use of analgesics and all consultations with primary-care physicians, physiotherapists, and other health-care providers were reported every week in a diary kept by the patient. The diaries were collected and checked by an administrative assistant during the subsequent visit to the research center.

#### Power of the Study

We calculated that twenty-five subjects were needed for each group. This sample size accounted for a 10% loss to follow-up, a type-I error rate of 0.05, and a power of 0.8. The assumptions of a delta of 3.0 points in pain rating on the numeric rating scale and a standard deviation of 2.0 were conservatively based on the data of previous studies<sup>13,20,28-30</sup>.

#### Statistical Analysis

The primary aim of this study was to compare the clinical outcome after eccentric training and after repetitive low-energy shock wave therapy without local anesthesia. The primary efficacy end point was prospectively defined as improvement of the VISA-A score from baseline to the four-month follow-up evaluation. With two time-points available for the main outcome criteria, a difference-in-difference model was applied.

Changes in scores over time for every patient were calculated by subtracting the results at baseline from those at the time of follow-up. The main analysis was performed on an intention-to-treat basis.

Summarizations were performed separately for each treatment group. Descriptive statistics are reported. Continuous variables were summarized within management groups with use of the mean, standard deviation, median, and range. Categorical variables were summarized within treatment groups with use of the mean and percentage.

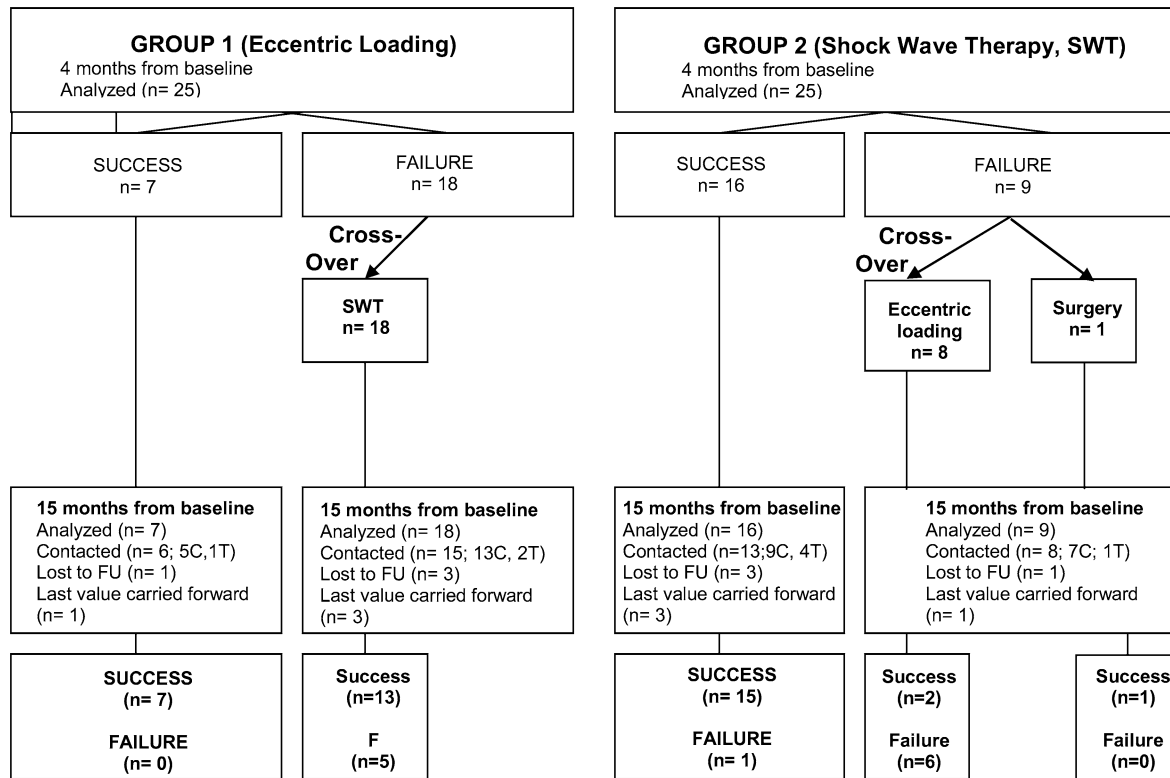


Fig. 2

Breakdown of the findings at the fifteen-month follow-up evaluation with regard to the criteria for a successful outcome on the Likert scale, with a score of 1 or 2 indicating a successful result and a score of 3 through 6 indicating failure. C = clinical examination, T = telephone contact, and FU = follow-up.

For the comparison of mean improvement of the VISA-A score and the assessment with the numeric rating scale at four months from baseline, the Wilcoxon test was used. Missing responses (three of twenty-five in Group 1 and two of twenty-five in Group 2) were imputed as the last observation carried forward. In the present study, the last observation was defined as the last observed value before the initial treatment.

For the comparison of the number of patients who had at least 50% improvement in the pain score, the Wilcoxon test was performed. Analysis was based on intention-to-treat.

Differences in improvement between the groups for continuous outcomes were analyzed by one-way analysis of variance.

## Results

### Results at Four Months from Baseline

Five patients were lost to follow-up. Two patients from Group 1 discontinued the intervention because of persistent pain. One patient refused to attend the follow-up visit but still had pain as reported on the telephone. Two patients in Group 2 refused to attend, but they reported by telephone that they were pain-free. For these five patients, outcome analysis was completed with use of the last (i.e., initial) set of data provided by each patient. Of the twenty-five patients in Group 1, twenty-one reported they had done the exercises daily, twice a day.

### VISA-A Score

The mean VISA-A score before the interventions ( $52.7 \pm 8.4$  for Group 1 and  $53.2 \pm 5.8$  for Group 2) showed no significant difference between the two groups. At the four-month follow-up, both groups showed significantly improved mean scores ( $63.4 \pm 12.0$  for Group 1 and  $79.4 \pm 10.4$  for Group 2) ( $p = 0.005$ ) (Table II). Information on how treatment influenced the subscales of the VISA-A scale is given in a table in the Appendix.

### General Assessment

Seven patients (28%) in Group 1 and sixteen patients (64%) in Group 2 scored the outcome after treatment as 1 (completely recovered) or 2 (much improved) on the Likert scale. This difference was significant ( $p < 0.020$ ). The remaining patients could not return to their normal levels of activity, as pain interfered substantially with daily activities at the four-month follow-up (Table II).

### Pain

The results of load-induced pain assessment before the interventions (mean,  $6.8 \pm 1.0$  for Group 1 and  $7.0 \pm 0.8$  for Group 2) showed no significant difference between the groups. At the four-month follow-up, both groups demonstrated improvement (mean,  $5.0 \pm 2.3$  for Group 1 and  $3.0 \pm 2.3$  for Group 2), with significantly better results for Group 2 than Group 1

( $p = 0.004$ ). Nineteen patients in Group 1 compared with seven patients in Group 2 reported that they had used paracetamol or naproxen; the difference was significant ( $p < 0.001$ ) (Table II).

#### Pain Threshold

At the beginning of the study, the mean pain threshold values for the groups ( $1.4 \pm 0.7$  kg for Group 1 and  $1.6 \pm 0.8$  kg for Group 2) were not significantly different. At the four-month follow-up, both groups showed a higher mean pain threshold ( $2.2 \pm 1.6$  kg for Group 1 and  $3.5 \pm 1.1$  for Group 2) than before treatment; the difference between the groups was significant ( $p = 0.002$ ) (Table II).

#### Tenderness

In the assessment of tenderness with use of the numeric rating scale, there was no significant difference between the groups before treatment (mean,  $6.2 \pm 3.7$  for Group 1 and  $6.5 \pm 3.4$  for Group 2). At the four-month follow-up, both groups showed improvement (mean,  $4.4 \pm 3.2$  for Group 1 and  $2.4 \pm 4.2$  for Group 2); the difference between the groups was significant ( $p = 0.021$ ) (Table II).

#### Side Effects

There were no serious complications. In all patients, transient reddening of the skin occurred after low-energy shock wave treatment, but there was no bruising. No device-related complications occurred. The patients reported aching in the calf after eccentric loading. During the study period, no patient sustained a rupture of the Achilles tendon.

#### Results at Fifteen Months from Baseline

As the patients were permitted to cross over after four months of treatment, all eighteen patients who had a poor outcome in Group 1 and eight of nine patients who had a poor outcome in Group 2 decided to cross over. The remaining patient from Group 2 opted for surgical treatment (Fig. 2). At fifteen months from baseline, no side effects were reported from either treatment group. During the study period, no patient who was seen in a follow-up evaluation or was contacted by telephone had sustained a rupture of the Achilles tendon.

#### Discussion

Insertional Achilles tendinopathy is a common problem for professional and recreational athletes, yet its etiology and pathogenesis are unknown. Today, tendinopathy is understood as a failed healing response of the extracellular matrix<sup>3,31-33</sup>. Although tendon biopsies show an absence of inflammatory cell infiltration, anti-inflammatory agents (nonsteroidal anti-inflammatory drugs and corticosteroidal injections) are still commonly used<sup>34-38</sup>. Evidence for the effectiveness of any available drug treatment regime is at best controversial<sup>9</sup>.

If nonoperative treatment fails in patients with Haglund disease when a deformity of the calcaneus is present, surgery may be indicated. Open or endoscopic surgical procedures have had reported success rates of  $\geq 80\%$ , but there are no data from prospective, randomized, controlled studies<sup>4,6,39,40</sup>. Hence,

our knowledge regarding the treatment efficacy of surgical procedures is based solely on clinical experience and descriptive studies. Postoperatively, there may be a need for immobilization and for reduced weight-bearing. Perioperatively, complication rates have been reported to be approximately 10%<sup>41,42</sup>, and they have included rupture, keloid formation, nerve damage (especially the sural nerve), poor healing, infection, bleeding and hematoma formation, wound dehiscence, and deep vein thrombosis.

Scandinavian researchers have developed an eccentric calf-muscle training program as an alternative to surgical treatment. Although the intervention received by the individual patient can vary within the training programs, those investigators have demonstrated that painful eccentric calf-muscle training can provide excellent short-term results in up to 89% of patients with chronic painful midsubstance Achilles tendinopathy<sup>12-14,25</sup>. However, the good results in those studies recently have been challenged<sup>15,24,43,44</sup>.

The data from the current study support the results from an uncontrolled small Scandinavian case series of thirty-one patients with insertional Achilles tendinopathy. In that study, Fahlstrom et al.<sup>13</sup> found that only ten of the patients had good results with eccentric calf-muscle training, and they could not explain why the treatment led to satisfactory results for only 32% of the patients with insertional pain compared with 89% of the patients with midsubstance pain. They speculated that the eccentric training might not have an effect on a mechanical problem, in which the calcaneus impinges on a chronically inflamed bursa and/or tendon<sup>38</sup>. In another uncontrolled small series of ten patients, however, Knobloch<sup>45</sup> initiated a twelve-week daily regimen of home-based eccentric training and found that the mean score for pain was significantly reduced from 6 to 3 points in the insertional tendinopathy group.

Low-energy shock wave therapy stimulates soft-tissue healing, enhances angiogenesis, and inhibits pain receptors<sup>2,46-50</sup>. Pilot studies investigating the effects of shock wave therapy on insertional and noninsertional Achilles tendinopathy have been promising<sup>16,51,52</sup>, and all three randomized controlled trials, which used repetitive shock wave treatment without local anesthesia at weekly intervals with a primary follow-up of at least twelve weeks after treatment, found that shock wave therapy in the treatment of midsubstance Achilles tendinopathy was substantially more effective than other treatments<sup>17,20,53</sup>. In the largest study, Rompe et al.<sup>20</sup> enrolled seventy-five patients with a chronic recalcitrant tendinopathy of the midsubstance of the Achilles tendon in a three-armed randomized comparison of eccentric loading, repetitive low-energy shock wave therapy, and a wait-and-see policy. At four months from baseline, 60%, 52%, and 24% of the patients, respectively, reported that they had completely recovered or were much improved. For all outcome measures, eccentric loading and shock wave therapy did not differ significantly, but they showed substantially better results than the wait-and-see policy. Deviating from the treatment concept outlined above, Costa et al.<sup>18</sup> reported a randomized, placebo-controlled trial in forty-nine patients with both noninsertional and insertional Achilles tendinopathy.



Using repetitive low-energy shock wave therapy at monthly intervals, with the primary follow-up of four weeks after therapy, they found no difference in pain relief between the shock wave therapy group and the control group.

The current study, to our knowledge, is the first randomized, controlled investigation limited entirely to the insertional form of Achilles tendinopathy. In our cohort of fifty patients with chronic pain, those managed with repetitive low-energy shock wave therapy showed more favorable results at four months than those managed with a twelve-week eccentric loading regimen with regard to the VISA-A score, pain rating, pain threshold, and tenderness. According to the scores on the Likert scale, 64% of the patients who had shock wave therapy compared with 28% of those who had eccentric loading reported that they were completely recovered or much improved at four months.

The present trial has some limitations. Treatment was not blinded, but that was unavoidable in this setting. As the study was designed pragmatically in a primary-care setting, implementation of a blinded and unbiased assessment of outcome was also difficult. The independent observer may have become aware of the treatment being received by patients in some instances. However, as the assistant was not directly involved in the management of patients, it is unlikely that this would have biased the results. Another potential weakness is the relatively small number of patients included. Nevertheless, significant and clinically important differences were observed between the two study groups at the time of the four-month follow-up. A potential bias derived from the senior author demonstrating how to perform eccentric loading cannot be ruled out; however, exactly the same teaching concept led to a convincing success rate of 60% in a controlled trial on patients with noninsertional Achilles tendinopathy<sup>20</sup>. Even the choice of the primary outcome measure might distort the comparison, but it is the best validated measure available to date<sup>4,24</sup>. This study provides no reliable data on long-term follow-up. In view of the fact that all participants were aware of the individual treatment procedure from the beginning and at any point of time during the study and that there was a crossover of eighteen of the twenty-five patients in Group 1 and eight of the twenty-five patients in Group 2, a diminishing number of participants available for analysis over time, and the possibility that concomitant interventions may have been used in the various subgroups, the results after the four-month observer-blinded assessment need to be interpreted cautiously. However, it appears that the results of shock wave therapy were sustained during the one-year period following treatment. This was the case also for the seven patients who had reported that they were completely recovered or much improved after the eccentric loading exercises.

From an economic standpoint, eccentric loading as implemented in the present study was the less expensive procedure, but it was less effective. In the future, the expense differential may become less as recent improvements in technology have helped to make shock wave therapy less expensive and easier to implement.

Overall, the role of eccentric loading and of shock wave therapy in the management of insertional Achilles tendinopathy has yet to be defined. On the basis of findings in the present study, we leave the choice of the modality up to our patients. We acknowledge that, in an environment where cost containment is paramount, primary implementation of a shock wave therapy regimen instead of eccentric exercises may be considered inappropriate, although the success rate for eccentric loading was only 28%.

From an economic standpoint, we previously suggested that consideration should be given to a sequential approach for the treatment of recalcitrant noninsertional Achilles tendinopathy, whereby shock wave therapy is used in patients in whom treatment with an eccentric exercise loading program has failed<sup>20</sup>. However, the current study demonstrated eccentric loading to be frequently ineffective for the treatment of insertional Achilles tendinopathy. For these patients, it may therefore be wiser to start with shock wave therapy.

The results of shock wave therapy as applied in this study were consistent with those in several level-I therapeutic studies<sup>54-57</sup> that provided evidence for a distinct role for shock wave therapy in the treatment of other insertional tendon disorders, such as lateral elbow tendinopathy or plantar fasciitis, under the following circumstances: (1) the application of 1500 to 2000 shocks of low-energy flux density (0.08 to 0.15 mJ/mm<sup>2</sup>) is used, (2) the application is directed to the site of maximal discomfort (with patient guidance), (3) no local anesthesia is used, (4) applications are done in weekly intervals (three or four applications), and (5) patients are followed for at least three months after the last application. Clinical success (a reduction of pain by >50%) could then be expected to be approximately 60% compared with approximately 30% after placebo treatment. It was particularly important that no local anesthetic was injected before shock wave therapy, as doing so led to inferior results<sup>2</sup>.

In conclusion, the results of this randomized, controlled trial, focusing exclusively on patients with recalcitrant insertional Achilles tendinopathy, demonstrate that the probability for recovery is significantly lower after eccentric loading as applied in the present study compared with repetitive low-energy shock wave therapy as applied in the study. Because it circumvents the need for immobilization and for reduced weight-bearing and because it is associated with virtually no side effects or morbidity and does not require any time lost from work, shock wave therapy should be regarded as an alternative treatment to surgery. Given the small size of the trial, the fact that it was not blinded, and the potential biases and confounders, this study falls under the “hypothesis-generating” category. Further studies are needed to confirm the results, and to ascertain whether combined eccentric training and shock wave therapy will result in higher success rates.

## Appendix

 A table showing the VISA-A subscale scores is available with the electronic versions of this article, on our web site at

jbjs.org (go to the article citation and click on "Supplementary Material") and on our quarterly CD-ROM (call our subscription department, at 781-449-9780, to order the CD-ROM). ■

Jan D. Rompe, MD  
OrthoTrauma Evaluation Center, Hans-Zoeller Strasse 83, D-55130  
Mainz, Germany. E-mail address: profrompe@web.de

John Furia, MD  
Sun Orthopaedics Group, 900 Buffalo Road, Lewisburg, PA 17837. E-mail  
address: jfuria@ptd.net

Nicola Maffulli, MD, PhD, FRCS(Orth)  
Department of Trauma and Orthopaedic Surgery, Keele  
University School of Medicine, Thornburrow Drive, Hartshill,  
Stoke on Trent, Staffordshire ST4 7QB, England.  
E-mail address: n.maffulli@keele.ac.uk

## References

- Paavola M, Kannus P, Jarvinen TA, Khan K, Jozsa L, Jarvinen M. Achilles tendinopathy. *J Bone Joint Surg Am.* 2002;84:2062-76.
- Furia JP, Rompe JD. Extracorporeal shock wave therapy in the treatment of chronic plantar fasciitis and Achilles tendinopathy. *Curr Opin Orthop.* 2007;18:102-11.
- Khan KM, Cook JL, Kannus P, Maffulli N, Bonar SF. Time to abandon the "tendinitis" myth. *BMJ.* 2002;324:626-7.
- Maffulli N, Sharma P, Luscombe KL. Achilles tendinopathy: aetiology and management. *J R Soc Med.* 2004;97:472-6.
- Maffulli N, Kenward MG, Testa V, Capasso G, Regine R, King JB. Clinical diagnosis of Achilles tendinopathy with tendinosis. *Clin J Sport Med.* 2003;13:11-5.
- Krishna Sayana M, Maffulli N. Insertional Achilles tendinopathy. *Foot Ankle Clin.* 2005;10:309-20.
- Magra M, Maffulli N. Nonsteroidal antiinflammatory drugs in tendinopathy: friend or foe. *Clin J Sport Med.* 2006;16:1-3.
- Paoloni JA, Appleyard RC, Nelson J, Murrell GA. Topical glyceryl trinitrate treatment of chronic noninsertional achilles tendinopathy. A randomized, double-blind, placebo-controlled trial. *J Bone Joint Surg Am.* 2004;86:916-22.
- McLauchlan GJ, Handoll HH. Interventions for treating acute and chronic Achilles tendinitis. *Cochrane Database Syst Rev.* 2001;2:CD000232.
- Manias P, Stasinopoulos D. A controlled clinical pilot trial to study the effectiveness of ice as a supplement to the exercise programme for the management of lateral elbow tendinopathy. *Br J Sports Med.* 2006;40:81-5.
- Stasinopoulos D, Stasinopoulos K, Johnson MI. An exercise programme for the management of lateral elbow tendinopathy. *Br J Sports Med.* 2006;40:81-5.
- Alfredson H. The chronic painful Achilles and patellar tendon: research on basic biology and treatment. *Scand J Med Sci Sports.* 2005;15:252-9.
- Fahlstrom M, Jonsson P, Lorentzon R, Alfredson H. Chronic Achilles tendon pain treated with eccentric calf-muscle training. *Knee Surg Sports Traumatol Arthrosc.* 2003;11:327-33.
- Ohberg L, Lorentzon R, Alfredson H. Eccentric training in patients with chronic Achilles tendinosis: normalised tendon structure and decreased thickness at follow up. *Br J Sports Med.* 2004;38:8-11.
- Woodley BL, Newsham-West RJ, Baxter GD. Chronic tendinopathy: effectiveness of eccentric exercise. *Br J Sports Med.* 2007;41:188-99.
- Furia JP. High-energy extracorporeal shock wave therapy as a treatment for insertional Achilles tendinopathy. *Am J Sports Med.* 2006;34:733-40.
- Astore F, Sansone V, De Marchi F. Extracorporeal shock wave therapy for tendinopathy of Achilles. Read at the 23rd Isokinetic Congress on the Rehabilitation of Sports Muscle and Tendon Injuries; 2004; Turin, Italy.
- Costa M, Shepstone L, Donell S, Thomas T. Shock wave therapy for chronic Achilles tendon pain: a randomized placebo-controlled trial. *Clin Orthop Relat Res.* 2005;440:199-204.
- Rompe JD. Shock wave therapy for chronic Achilles tendon pain: a randomized placebo-controlled trial. *Clin Orthop Relat Res.* 2006;445:276-7. Author reply 277.
- Rompe JD, Nafe B, Furia J, Maffulli N. Eccentric loading, shock wave treatment, or a wait-and-see policy for tendinopathy of the main body of tendo Achillis: a randomized controlled trial. *Am J Sports Med.* 2007;35:374-83.
- Williams JG. Achilles tendon lesions in sport. *Sports Med.* 1993;16:216-20.
- Richards PJ, Win T, Jones PW. The distribution of microvascular response in Achilles tendinopathy assessed by colour and power Doppler. *Skeletal Radiol.* 2005;34:336-42.
- Myerson MS, McGarvey W. Disorders of the Achilles tendon insertion and Achilles tendinitis. *Instr Course Lect.* 1999;48:211-8.
- Sayana MK, Maffulli N. Eccentric calf muscle training in non-athletic patients with Achilles tendinopathy. *J Sci Med Sport.* 2007;10:52-8.
- Roos EM, Engstrom M, Lagerquist A, Soderberg B. Clinical improvement after 6 weeks of eccentric exercise in patients with mid-portion Achilles tendinopathy—a randomized trial with 1-year follow-up. *Scand J Med Sci Sports.* 2004;14:286-95.
- Robinson JM, Cook JL, Purdam C, Visentini PJ, Ross J, Maffulli N, Taunton JE, Khan KM; Victorian Institute Of Sport Tendon Study Group. The VISA-A questionnaire: a valid and reliable index of the clinical severity of Achilles tendinopathy. *Br J Sports Med.* 2001;35:335-41.
- van der Windt DA, Koes BW, Devillé W, Boeke AJ, de Jong BA, Bouter LM. Effectiveness of corticosteroid injections versus physiotherapy for treatment of painful stiff shoulder in primary care: randomised trial. *BMJ.* 1998;317:1292-6.
- Rompe JD, Schoellner C, Nafe B. Evaluation of low-energy extracorporeal shock-wave application for treatment of chronic plantar fasciitis. *J Bone Joint Surg Am.* 2002;84:335-41.
- Rompe JD, Decking J, Schoellner C, Theis C. Repetitive low-energy shock wave treatment for chronic lateral epicondylitis in tennis players. *Am J Sports Med.* 2004;32:734-43.
- Rompe JD, Meurer A, Nafe B, Hofmann A, Gerdesmeyer L. Repetitive low-energy shock wave application without local anesthesia is more efficient than repetitive low-energy shock wave application with local anesthesia in the treatment of chronic plantar fasciitis. *J Orthop Res.* 2005;23:931-41.
- Sharma P, Maffulli N. Tendon injury and tendinopathy: healing and repair. *J Bone Joint Surg Am.* 2005;87:187-202.
- Kannus P, Jozsa L. Histopathological changes preceding spontaneous rupture of a tendon. A controlled study of 891 patients. *J Bone Joint Surg Am.* 1991;73:1507-25.
- Wang JHC, Iosifidis MI, Fu FH. Biomechanical basis for tendinopathy. *Clin Orthop Relat Res.* 2006;443:320-32.
- Gill SS, Gelbke MK, Mattson SL, Anderson MW, Hurwitz SR. Fluoroscopically guided low-volume peritendinous corticosteroid injection for Achilles tendinopathy. A safety study. *J Bone Joint Surg Am.* 2004;86:802-6.
- Hugate R, Pennypacker J, Saunders M, Juliano P. The effects of intra-tendinous and retrocalcaneal intrabursal injections of corticosteroid on the biomechanical properties of rabbit Achilles tendons. *J Bone Joint Surg Am.* 2004;86:794-801.
- Tsai WC, Hsu CC, Chen CP, Chen MJ, Lin MS, Pang JH. Ibuprofen inhibition of tendon cell migration and down-regulation of paxillin expression. *J Orthop Res.* 2006;24:551-8.
- Nichols AW. Complications associated with the use of corticosteroids in the treatment of athletic injuries. *Clin J Sport Med.* 2005;15:370-5.
- Alfredson H, Cook J. Pain in the Achilles region. In: Brukner P, Khan K, editors. *Clinical Sports Medicine.* 3rd ed. Sydney: McGraw-Hill; 2006. p 590-611.
- Wagner E, Gould JS, Kneidel M, Fleisig GS, Fowler R. Technique and results of Achilles tendon detachment and reconstruction for insertional Achilles tendinosis. *Foot Ankle Int.* 2006;27:677-84.
- Maquirriain J. Endoscopic Achilles tenodesis: a surgical alternative for chronic insertional tendinopathy. *Knee Surg Sports Traumatol Arthrosc.* 2007;15:940-3.

- 41.** Young JS, Kumta, SM, Maffulli N. Achilles tendon rupture and tendinopathy: management of complications. *Foot Ankle Clin.* 2005;10:371-82.
- 42.** Paavola M, Orava S, Leppilahti J, Kannus P, Jarvinen M. Chronic Achilles tendon overuse injury: complications after surgical treatment. An analysis of 432 consecutive patients. *Am J Sports Med.* 2000;28:77-82.
- 43.** van Snellenberg W, Wiley JP, Brunet G. Achilles tendon pain intensity and level of neovascularization in athletes as determined by color Doppler ultrasound. *Scand J Med Sci Sports.* 2006; Epub ahead of print.
- 44.** Kingma JJ, de Knikker R, Wittink HW, Takken T. Eccentric overload training in patients with a chronic Achilles tendinopathy: a systematic review. *Br J Sports Med.* 2007;41:e3.
- 45.** Knobloch K. Eccentric training in Achilles tendinopathy: is it harmful to tendon microcirculation? *Br J Sports Med.* 2007;41:e2.
- 46.** Chen YJ, Wang CJ, Yang KD, Kuo YR, Huang HC, Huang YT, Sun YC, Wang FS. Extracorporeal shock waves promote healing of collagenase-induced Achilles tendinitis and increase TGF-beta1 and IGF-I expression. *J Orthop Res.* 2004;22:854-61.
- 47.** Ohtori S, Inoue G, Mannoji C, Saisu T, Takahashi K, Mitsunashi S, Wada Y, Takahashi K, Yamagata M, Moriya H. Shock wave application to rat skin induces degeneration and reinnervation of sensory nerve fibres. *Neurosci Lett.* 2001;315:57-60.
- 48.** Takahashi N, Ohtori S, Saisu T, Moriya H, Wada Y. Second application of low-energy shock waves has a cumulative effect on free nerve endings. *Clin Orthop Relat Res.* 2006;443:315-9.
- 49.** Wang CJ, Wang FS, Yang KD, Weng LH, Hsu CC, Huang CS, Yang LC. Shock wave therapy induces neovascularization at the tendon-bone junction. A study in rabbits. *J Orthop Res.* 2003;21:984-9.
- 50.** Wang CJ, Wang FS, Yang KD, Weng LH, Sun YC, Yang YJ. The effect of shock wave treatment at the tendon-bone interface—an histomorphological and biomechanical study in rabbits. *J Orthop Res.* 2005;23:274-80.
- 51.** Lohrer H, Scholl J, Arentz S. [Achilles tendinopathy and patellar tendinopathy. Results of radial shockwave therapy in patients with unsuccessfully treated tendinoses]. *Sportverl Sportschad.* 2002;16:108-14. German.
- 52.** Perlick L, Schiffmann R, Kraft CN, Wallny T, Diederich O. [Extracorporeal shock wave treatment of the achilles tendinitis: Experimental and preliminary clinical results]. *Z Orthop Ihre Grenzgeb.* 2002;140:275-80. German.
- 53.** Peers K. Extracorporeal shock wave therapy in chronic achilles and patellar tendinopathy. Leuven, Belgium: Leuven University Press; 2003.
- 54.** Rompe JD, Decking J, Schoellner C, Theis C. Repetitive low-energy shock wave treatment for chronic lateral epicondylitis in tennis plagues. *Am J Sports Med.* 2004;32:734-43.
- 55.** Pettrone FA, McCall BR. Extracorporeal shock wave therapy without local anesthesia for chronic lateral epicondylitis. *J Bone Joint Surg Am.* 2005;87:1297-1304.
- 56.** Rompe JD, Maffulli N. Repetitive shock wave therapy for lateral elbow tendinopathy (tennis elbow): a systematic and qualitative analysis. *Br Med Bull.* 2007;83:355-78.
- 57.** Rompe JD, Furia J, Weil L, Maffulli N. Shock wave therapy for chronic plantar fasciopathy. *Br Med Bull.* 2007;81-82:183-208.